

A computational modeling for the detection of diabetic retinopathy severity

Pavan Kumar Mishra¹, Abhijit Sinha¹, Kaveti Ravi Teja¹, Nitin Bhojwani¹, Sagar Sahu¹ & Awanish Kumar^{2*}

¹Department of Information Technology, National Institute of Technology, Raipur, Chhattisgarh, India; ²Department of Biotechnology, National Institute of Technology, Raipur, Chhattisgarh, India; Awanish Kumar - Email: drawanishkr@gmail.com; *Corresponding author

Received June 17, 2014; Revised August 06, 2014; Accepted August 07, 2014; Published September 30, 2014

Abstract:

Prolonged diabetes ultimately leads to Diabetic Retinopathy (DR) which is one of the leading causes of preventable blindness in the world. Through advanced image analysis techniques are used for abnormalities detection in retina that define and correlate the severity of DR. A thorough study is done in this area in recent past years and on the basis of these studies we have developed a computer based prediction model that is used to determine the severity of DR. To identify severity DR, we have analyzed the human eye image. We have extracted some important features from human eye image i.e. Blood Artery, Optical disc, Exudates. Based on these image and data we have designed an automated system for the determination of DR severity. This automated DR severity assessment methods can be used to predict the clinical case and conditions when young clinicians would agree or disagree with their more experienced fellow members. The algorithms described in this study may be used in clinical practice to validate or invalidate the diagnoses. Algorithms or method developed here may also be used for pooling diagnostic knowledge for serving mankind. Here we have described a computational based low cost retinal diagnostic approach which can aid an ophthalmologist to quickly diagnose the various stages of DR. This system can accept retinal images and can successfully detect any pathological condition associated with DR.

Keywords: *Diabetic retinopathy*, fundus, blood vessel, optic disc, exudates, image processing.

Background:

Diabetic retinopathy (DR) is one of the leading chronic diseases, caused by complications of diabetes that eventually leads to the blindness. It is estimated that diabetes mellitus type 2 affects 4 percent of the world's population and almost half of whom have some degree of DR at any given time [1]. In India, there has been epidemic increase in type 2 diabetes and DR as reported by World Health Organization (WHO) [2]. Visual disability from diabetes is thus a substantial public health problem; however this morbidity is largely preventable and treatable. Taking effective precautionary steps at right time, the quality of life may be preserved [3]. DR is broadly classified in two categories: i) Nonproliferative DR (NPDR) and ii) Proliferative DR (PDR). NPDR happens when the blood vessels leak and then close. PDR is the advanced stage of DR where the new abnormal blood vessels grow. Due to lack of oxygen, it causes fragile new blood vessel grow along retina and filled the eye with clear gel like vitreous humour. If treatment is delayed this can cause vessel to bleed and cause cloud vision and destroy retina.

Therefore, an automated DR diagnostic system is required and will have to be implemented [2, 3]. Ophthalmologists use color fundus images of eye, optic disk (bright circular regions of eye where blood vessels emanate) and other features (exudates, microaneurysms, hemorrhages, fovea etc) to study the diseases

like DR. Exudates are yellow lipid deposits which appear as bright yellow lesions. Microaneurysms are small ocular pouches in eye caused by local distension of capillary walls and appear as small red dots. DR may lead to bigger blood clots called hemorrhages. The fovea is defined as center of retina and is region of highest visual acuity. The thicknesses of blood vessels in optic disk, spatial distribution of exudates, microaneurysms and hemorrhages, especially in relation to the fovea can be used to determine the severity of DR [4]. The present research work is the use of DR patient's eye images to extract various discussed features and develop a computer based algorithm and model for quick and reliable detection of DR severity.

Methodology:

Blood vessel detection

Automated detection of blood vessel is difficult task as the diameter of blood vessel can vary from very small to large. Most blood vessel detection algorithms are window based and emphasis the surrounding window around a given pixel that matches with a predefined model. The detection of blood vessels using Gabor filters and scheme production is in frequent use. The proposed method is beneficiary for both the detection of large and small vessels but also good for removing the noise and enhancement of responses of line filters. The stated method for vessels detection involves the following steps:

Inverted Green Channel

The analysis of RGB components of fundus images show that Green channel has best background contrast whereas Blue and Red Channel are very noisy. Therefore the input image to our system has green channel extracted only. An iterative algorithm proposed in is used to remove the strong contrast between the retinal fundus and image outside the aperture [5]. The Gabor wavelet transform is implemented using the fast fourier transformation algorithm. 2-D Gabor wavelet has directional selectiveness capability of detecting oriented features and fine tuning to specific frequency [6].

Line Operators

We are focused on calculating two features at each pixel of image using orthogonal line operators. The first feature includes calculation of difference $S = L - N$ where L denotes the maximum gray level obtained when the line operator is convoluted up to 360° for each pixel and N denotes average gray level. S is calculated for squared window centered on each pixel [7]. The second feature of line operator is evaluated along gray level of line orthogonal to the first feature. This line has three pixels length centered at the midpoint of the basic line operator and perpendicular to it. Its average value is denoted by L_0 and its strength is obtained by $S_0 = L_0 - N$. This L_0 separates the pixels of thin vessels as it would be very low and pixels in background will have high L_0 value. On the basis of the pixel density of blood vessel to the pixel density is used to estimate level of diabetes (normal, mild, moderate and severe). In this case number of pixels occupied by the blood vessel was calculated and then the number of pixels in eye of the fundus image was calculated. After that the ratio of blood vessel by eye pixels count was obtained and store in a text file as 'data.txt'

which is going to be used as training data. Now training data were used to train kNN classifier.

Optic Disc Detection

It is mostly circular or elliptical in shape and its color is bright yellowish or white [8]. Its intensity range lie in red color range hence it is good to do analysis on red channel (Please see supplementary material further explanation and equation).

Exudates detection

Exudates are the darkest spots in the retinal images which have sharp boundaries with black background. For finding the boundary of each exudate we have applied the morphological operation on the retinal image. Exudates respond when dilation is applied on the image because exudates have brighter edges and dark yellow color. It occupies most of the part of the green channel we apply dilation on the green channel of the eye image to extract exudates [13]. In order to perform dilation we have built-in Mat lab function `imdilate`. We have selected rectangle with height and width as 25 and 25 using this we have developed a matrix which stores information of this object and traverse over the input image and dilate it. We have dilated the image to remove the blood vessels. After applying dilation on the image with SE as rectangle then we got an image with no blood vessels in it [14]. We had applied dilation again with SE as disc on the original image then we will get an image with highlighted bright exudates with no blood vessels. Then we had subtracted the both outputs in order to get exudates with sharp edges with no blood vessels in it [15]. Exudates are bright yellow or white in color and have high intensity in the green channel. We have localize the exudate patches more accurately by taking all the candidate regions whose mean intensities in the green channel are greater than a fraction (obtained by training) of the maximum intensity in the channel [16]. After this the contours which satisfy both conditions remain in the output while other may be discarded [17]. We have extracted optical disc object from the original image then we subtracted both the outputs and the resultant output contain exudates only [18].

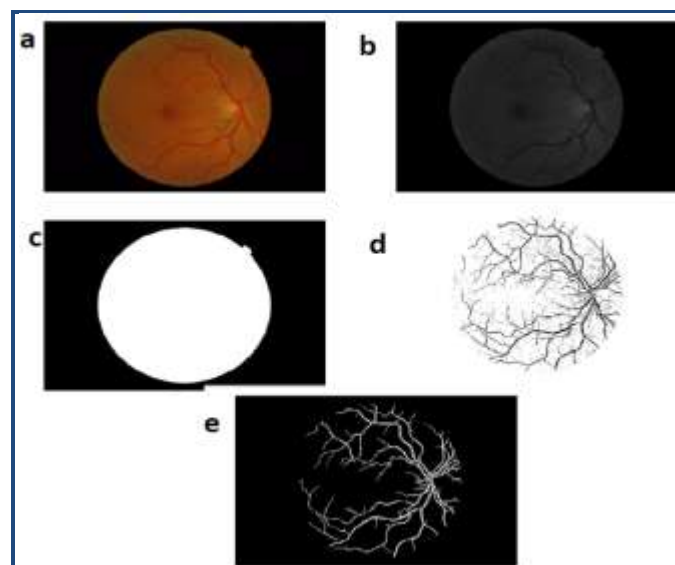


Figure 1: Automated blood vessel detection: a) Input Image b) Green channel of Image c) Mask eye of image d) Blood vessel after Gabor Filter e) Final Output Image.

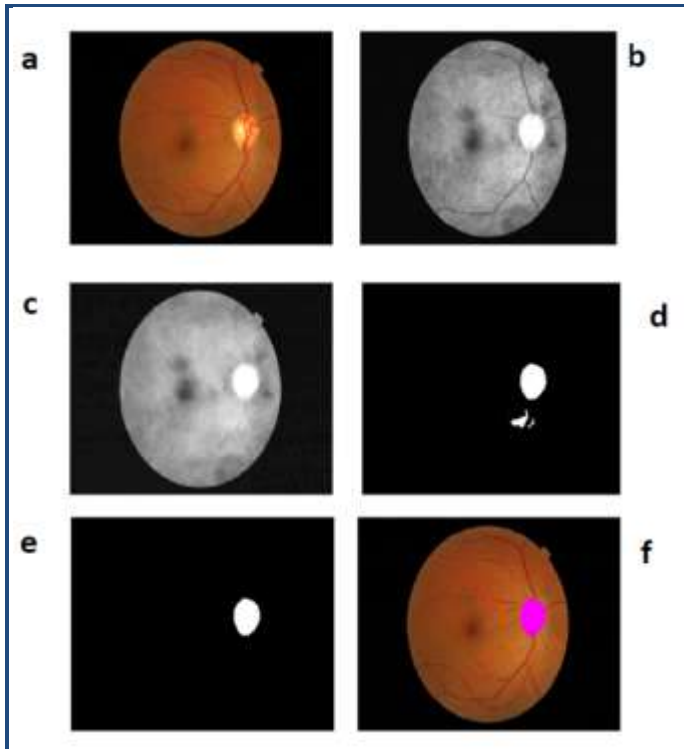


Figure 2: Set of multimodal photographs of eye analysed for optic disc detection **a)** Input Image **b)** Applying Adaptive Histogram Equalization **c)** After Closing Morphological Operation **d)** After Image Segmentation **e)** After removing small regions **f)** Optic Disc Mapped.

Results & Discussion:

The results were obtained from fundus images which were used for detection and diagnosis of DR. The individual segmentation modules were developed using MATLAB, later integrated with other computational approaches as mentioned in methodology. We have to determine the thickness of the blood vessels because diseased eye have more thick blood vessels when compared to normal eye. In order to determine the thickness of the blood vessels we had applied the edge detection algorithms like sobel operator, Morphological edge detector etc, through this we had calculated the thickness of the diseased blood vessels and compared with normal eye image data. In this way we have estimate the disease level and severity of DR (**Figure 1**). Image enhancement process has been applied on filtered image (**Figure 1a**) by using adaptive threshold as shown in figure 1b. The output image is a brighter and contains blood vessel and exudates that has to be removed. It is done by applying closing morphological operation (erosion and dilation) so that the blood vessel is removed from the image. The erosion operation narrows and remove blood vessel while the dilation operation restore the image without blood vessel as shown in **Figure 1c**. The image as shown in figure 1d consists of small bright spots that are mostly exudates or fats etc. Such small bright spots (that covers less than 1% pixels of image) are removed from the image by bwareaopen built-in method in Matlab as shown in **Figure 1e**. After that we have identified the size of the optical disc in eye because diseased eye have expanded optical disc size compare with standard eye data (**Figure 2**). In order to find boundaries and the border of the optical disc in the eye image, we have implemented

different algorithms as discussed in methodology. Hemorrhage is mainly caused due to clotting of blood these clotting of blood in eye is identified as dark spots. In diseased eye there is huge percentage of dark spots. So we have identified these dark spots in **Figure 3** as output image. The output image was binary threshold to a particular value such that image contains clear boundaries of the exudates. After getting the boundaries we have two types of exudates present in it soft exudates and hard exudates. Hard exudates have closed boundaries in the threshold image while the soft exudates breaks in the contours are connected by smoothing spines.

The complete flow chart of this study was given in to **Figure 4** in which the overall steps from pre processing of image to result and analyses have been shown. The total area occupied and the area occupied in the fovea region is calculated corresponding to the exudates, based on the number of pixels and the severity level was determined as none, mild, moderate and severe. **Figures 1, 2, 3** show the results of DR severity of a typical patient, based on the fundus image. **Table 1 & 2** show the pixel count of blood vessel and optic disc. Pixel density and eye ratio are listed in **Table 1 & 2** to know about the severity of DR. From the above datasets and results we may observe that the severity of disease on the basis of available image/data in the case of blood vessel vary as per the pixel density of the blood vessel. It confirms the hypothesis that increasing thickness of blood with severity leads to increase in the blood vessel density in the images. While in the case of optic disc the severity seems to be dependent on the ratio of area covered by optic disc on the eye image. More severity leads to lesser coverage of brighter optic disc area because we know that with severity the brightness of eye become lesser as compared to mild or moderate in which case the optic disc is bright and that are covered more than 2%. This study shows the feasibility of the computational model of the analysis of DR.

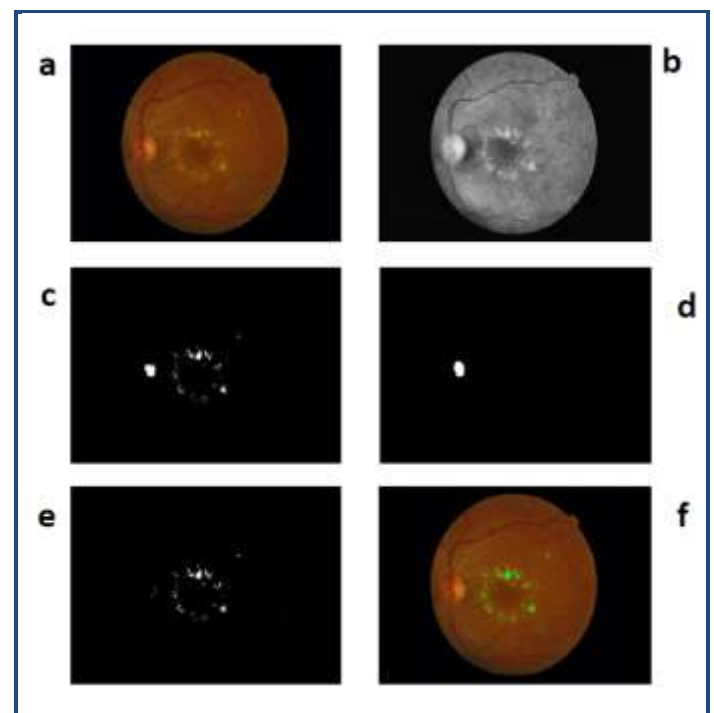


Figure 3: Set of multimodal photographs of eye for the detection of exudates **a)** Input Image **b)** Image enhancement **c)**

Image Segmentation d) Optic Disc segmentation e) Image Subtraction f) Output image.

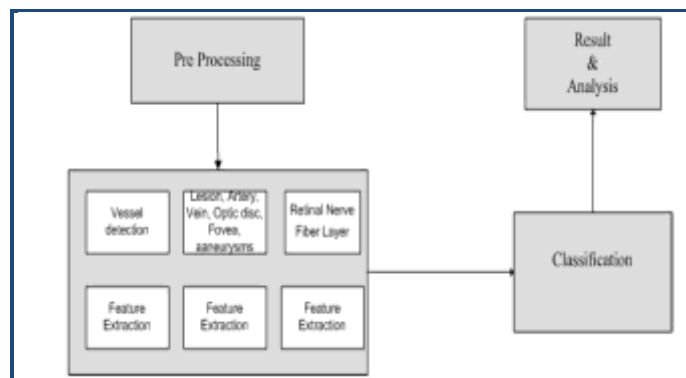


Figure 4: A flow chart for the detection of DR on the basis of computational approach.

Conclusion:

We implemented algorithms to extract features like blood vessels, exudates, optic disc and to find level of severity of these mentioned features in the input eye image. The algorithm implemented is automated so that every image diagnosis is not depends on human value for features. These generalized algorithms are independent of camera used ophthalmologist because the calculation doesn't depend on the size of pixels or dimension of image or format of image. Our techniques or algorithms are combined with some learning methods (KNN classification) for possibly even better results. We have mainly focused on adaptability and accuracy in this work and may implement these finding in new features extraction such as macula, fats and color of fundus image. We automate these features detection technique and increase the efficiency of the proposed algorithms.

Automation is where there is a room for improvement because the learning algorithm used are slower and much simpler method by introducing more new methods such as Neural networks, Support Vector Machine or Principal components Analysis. Further speed of the system can be enhance by introducing parallelism through CUDA, OpenCL libraries such that it can take advantage of hardware with the massive level of parallelism. Such a model/system can be of significant benefit for mass diagnosis in rural areas especially in India where patient to ophthalmologist ratio is high [19]. In this paper we have identified and concentrated on some features such as thickness of blood vessels, fovea region, and blood clotting area. On the basis of these feature we have estimated the condition of the DR patient and applied several images processing algorithm for finding the best result. For automatic classification we use KNN classifier that predict the severity

condition based on features value. A major advantage of this algorithm is that the accuracy achieved for detection is very high which implies greater accuracy of DR detection. Therefore, computational modelling and analyses done here can serve as foundation chunks for the advance research in DR and eventually help in their better management.

Conflict of Interest:

The authors have declared no conflict of interest.

Acknowledgement:

Authors are thankful to Dept. of Information Technology and Dept. of Biotechnology, NIT, Raipur, India for providing facility, space and resources for this work.

References:

- [1] Shaw JE *et al.* *Diabetes Res Clin Pract.* 2010 **87**: 4 [PMID: 19896746]
- [2] Raman R *et al.* *Ophthalmology.* 2009 **116**: 311 [PMID: 19084275]
- [3] Chobanian AV *N Engl J Med.* 2001 **16**: 534 [PMID: 11519509]
- [4] Thomas RL *et al.* *BMJ.* 2012 **22**: e874 [PMID: 22362115]
- [5] Jiménez S *et al.* *Arch Soc Esp Oftalmol* 2011 **86**: 277 [PMID: 21893260]
- [6] Heng LZ *et al.* *Diabet Med.* 2013 **30**: 640 [PMID: 23205608]
- [7] Rema M *et al.* *Invest Ophthalmol Vis Sci.* 2005 **46**: 2328 [PMID:15980218]
- [8] Rema M & Pradeepa R, *Indian J Med Res.* 2007 **125**: 297 [PMID: 17496357]
- [9] Choudhari KS *et al.* *Microsc Microanal.* 2013 **19**: 1061 [PMID: 23702082]
- [10] Kirbas C & Quek FKH, *Third IEEE Symposium on Bioinformatics and Bioengineering Proceedings*, 2003 vol. 1, pp.238-245
- [11] Lazar I & Hajdu A, *Conf Proc IEEE Eng Med Biol Soc.* 2012 1458-1461 [PMID: 23366176]
- [12] Abramoff MD *et al.* *Invest Ophthalmol Vis Sci* 2007 **48**: 1665 [PMID: 17389498]
- [13] Ward NP *et al.* *Ophthalmology.* 1989 **96**: 80 [PMID: 2919052]
- [14] Walter T *et al.* *IEEE Trans Med Imaging.* 2002 **21**:1236 [PMID: 12585705]
- [15] Sánchez Gutiérrez CI *et al.* *Arch Soc Esp Oftalmol.* 2004 **79**: 623 [PMID: 15627932]
- [16] Rahebi J *et al.* *J Med Syst.* 2014 **38**: 85 [PMID: 24957399]
- [17] Sinthanayothin C *et al.* *Br J Ophthalmol.* 1999 **83**: 902 [PMID: 10413690]
- [18] Yip HM *et al.* *Scientific World Journal.* 2014 **60**: 81 [PMID: 25133248]
- [19] McGavin DD, *Community Eye Health.* 1999 **12**: 32 [PMID: 17491991]

Edited by P Kanguane

Citation: Mishra *et al.* *Bioinformation* 10(9): 556-561 (2014)

License statement: This is an open-access article, which permits unrestricted use, distribution, and reproduction in any medium, for non-commercial purposes, provided the original author and source are credited

Supplementary material:

Methodology:

Optic Disc Detection

It is mostly circular or elliptical in shape and its color is bright yellowish or white [8]. Its intensity range lie in red color range hence it is good to do analysis on red channel. On the red channel of image median filter is applied for reduction of noise image is smoothened. There is a built in method enclose in Matlab which is fast and better compared to other implementation, it takes disk type structural element as parameter [9]. After that image undergoes segmentation process and so for automatic determining the threshold value for the segmentation Otsu Algorithm [10] is used. Otsu shows that minimizing the intra-class variance is the same as maximizing inter-class variance between a segmented foreground object and background:

$$\sigma_b^2(t) = \sigma^2 - \sigma_w^2(t) = \omega_1(t)\omega_2(t) [\mu_1(t) - \mu_2(t)]^2$$

which is expressed in terms of class probabilities ω_i and class means. μ_i The class probability $\omega_1(t)$ is computed from the histogram as t :

$$\omega_1(t) = \sum_0^t p(i)$$

While the class mean $\mu_1(t)$ is:

$$\mu_1(t) = \left[\sum_0^t p(i) x(i) \right] / \omega_1$$

Where $x(i)$ is the value at the centre of the i^{th} histogram bin & compute $\omega_2(t)$ and $\mu_2(t)$ on the right-hand side of the histogram for bins greater than t . Finally a binary image consist of the desired optic disc image was obtained. Then this binary image was used to map the optic disc back to original image [11]. In this case number of pixels occupied by the optic disc was calculated and then the number of pixels in eye of the fundus image was also calculated. After that a ratio of optic disc by eye pixels count was obtained and store in a text file as 'data.txt' which going to be used as training data for kNN classifier [12].

Table 1: Numerical values obtained from blood vessel analysis.

Pixel Count	Pixel Density of vessels	Severity of DR
373378	25.78689542	severe
199213	13.62358148	mild
180585	12.45912158	mild
134585	9.2105513	normal
379916	25.98302523	moderate
227490	15.57941537	mild
483927	33.13858056	severe
169689	11.6101289	normal
220901	15.10684161	mild
22382	33.86952772	severe
41458	21.97428259	severe
13952	25.9779917	Moderate
93254	16.03216955	moderate
19033	32.8251384	sever
176488	12.62021302	normal
165971	15.81185182	mild
132726	10.23572254	normal
122399	12.94393349	normal
122399	12.94393349	normal
124730	8.93953967	normal
217409	17.5617625	normal
153911	13.40142991	normal
231684	16.58566547	moderate
337484	24.91129314	moderate

Table 2: Numerical values obtained from eye ratio.

Pixel Count	OD/Eye Ratio	Severity of DR
27202	2.67884137	normal
37801	2.79027092	mild
22149	1.58559031	moderate
31649	2.75576051	normal
12104	0.86750732	moderate
35973	3.4271032	mild
11587	0.82948372	severe
38290	3.1955761	normal
44648	4.72161327	normal
35288	2.72138222	mild
30995	2.22071285	mild
10228	0.74789481	Severe
35973	3.4271032	mild
9233	0.72907454	moderate
56821	4.10149765	normal
123600	8.83832515	normal
18621	1.51176385	moderate
160416	2.29313835	moderate
0	0	severe
35869	2.45297367	mild
0	0	normal
0	0	mild
82100	5.61494217	severe
28156	1.92823429	normal
37493	2.56470769	normal
0	0	moderate
42831	2.93049892	normal
17765	1.21652002	severe